

Tongue-tie – exploding the myths

Tongue-tie occurs in 4-5% of babies. However, despite this appearing to be a relatively minor condition, there is huge debate about whether tongue-tie is clinically significant and as a result major differences exist concerning the policies for tongue-tie division. This article provides an overview of the different indications for tongue-tie division, and aims to explode some of the myths that have arisen.

Paul R V Johnson

MBChB, MA, MD, FRCS (Paed Surg)
Reader in Paediatric Surgery, University of Oxford and Consultant Paediatric Surgeon, John Radcliffe Hospital, Oxford

Ankyloglossia or ‘tongue-tie’ is a congenital anomaly caused by an abnormally tight lingual frenulum (the band of tissue that connects the tongue base to the floor of the mouth) and occurs more commonly in males than females¹. It has been reported to be present to some degree in as many as 11% of newborn babies, although the more widely quoted incidence is 2-5%^{2,4}. Until the 1950s, tongue-ties were divided routinely². However, since then there has been much debate amongst healthcare professionals about the clinical significance of tongue-ties and as a result major differences in opinion exist as to whether division of tongue-tie is necessary or not. Indeed, even when it is agreed that tongue-tie division is indicated, controversy also exists over the timing of division, the technique used for division, and even the exact definition of this condition⁵. In an interesting survey of over 1500 paediatricians, otolaryngologists, speech therapists, and lactation consultants in the USA, Messner confirmed major differences in approach to the management of tongue-tie, with paediatricians being the least likely to recommend division⁴. The aim of this review is to provide an evidence-based discussion of the indications for tongue-tie division. In particular the relationship between tongue-tie and breastfeeding, speech, oral hygiene, and social tongue movement will be addressed. To begin with however, it is important to be clear on the exact definition of tongue-tie.

Defining tongue-tie

In simple terms, tongue-tie is present when the lingual frenulum is attached close to the tongue tip, resulting in reduced tongue movement (FIGURE 1). However, in some cases of tongue-tie the attachment of the frenulum is to the proximal tongue base but the frenulum is shortened, resulting in

similar tongue restriction. These differences have lead to a seemingly simple condition being associated with a wide number of definitions, and as a result, considerable variability in reported incidence diagnosis and management.

The principle differences in definition relate to whether an anatomical or functional approach is adopted.

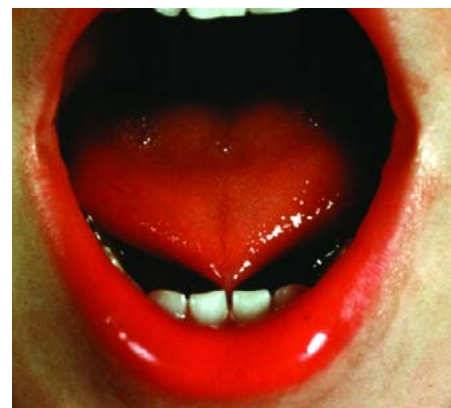


FIGURE 1 Untreated tongue-tie in an older child. Note that the frenulum extends to the tongue tip, although no forking of the tongue is present in this case.

Anatomical definitions

Anatomical definitions consist of descriptions of appearance of both tongue and frenulum, as well as absolute measurements. Descriptions include the appearance of the tongue when lifted, the elasticity of the lingual frenulum, the attachment of the frenulum to the tongue, and the attachment of the frenulum to the inferior alveolar ridge. Absolute measurements include the length of the lingual frenulum when the tongue is lifted, as well as the ‘free tongue’ length. The latter forms the basis for the Kotlow Classification of Ankyloglossia (TABLE 1). One of the problems with this precise definition is its impracticality. Measuring free tongue length in a screaming newborn can be quite a challenge!

Keywords

tongue-tie; ankyloglossia; breastfeeding; speech; frenotomy

Key points

Johnson, P.R.V. (2006) Tongue-tie – exploding the myths. *Infant* 2(3): 96-99.

1. There is considerable variation in reported incidence, diagnosis and management of tongue-tie.
2. The most useful assessment of tongue-tie is based on the position of frenular attachment to the tongue base, degree of maximal tongue tip protrusion and impairment of activities requiring tongue function.
3. There is evidence that tongue-tie division can improve breastfeeding in babies with tongue-tie having difficulty feeding, as well as improving oral hygiene and social tongue function.
4. Division is usually carried out before three months of age in babies with feeding difficulties or electively after six months for other indications.

Clinically Normal	>16 mm
Class I: Mild Ankyloglossia	12-16 mm
Class II: Moderate Ankyloglossia	8-11 mm
Class III: Severe Ankyloglossia	3-7 mm
Class IV: Complete Ankyloglossia	<3 mm

TABLE 1. Kotlow classification of ankyloglossia (tongue-tie). Based on 'free tongue' length.

Functional definitions

The simplest functional definition was outlined by Wallace as 'a condition in which the tip of the tongue cannot be protruded beyond the lower incisor teeth because of a short frenulum'¹. However, tongue movement is more complex than simple protrusion and as a result functional assessments have included tongue lateralisation, tongue lift, tongue spread, tongue 'cupping' and tongue 'snap back'. In an attempt to combine anatomical appearance and tongue function, Hazelbaker developed an assessment tool for the lingual frenulum (TABLE 2). In this assessment, five appearance items and seven function items are scored. Significant ankyloglossia is diagnosed if the total appearance score is 8 or less and/or the total function score total is 11 or less.

Whilst this detailed scoring system enables objective definition, assessment, and diagnosis of tongue-tie, its practicality for routine clinical assessment of infants is questionable. In clinical practice the most useful assessment of tongue-tie is based on the position of frenular attachment to the tongue base, degree of maximal tongue tip protrusion, and impairment of activities requiring tongue function. It is the latter point that is controversial and is the subject for the remainder of this review.

Indications for division

Most clinicians will agree on the position where a particular infant's lingual frenulum attaches to the tongue and how far that infant's tongue can protrude. However, even if frenular attachment is to the tongue tip and tongue movement significantly restricted, there is no consensus as to whether this actually causes a problem and whether it requires dividing. When evaluating the indications for tongue-tie division, it is important to

remember that, as with many aspects of medicine, association does not necessarily mean causation. Indeed, many adults report having had tongue-ties present since birth with minimal impairment of function. When then should tongue-tie be divided and what evidence is there that division is associated with improved function?

Breastfeeding

Over the last couple of decades there has been a major drive to encourage babies to breastfeed⁶. As a result there has been a greater reluctance to abandon breastfeeding if difficulties arise. This has re-opened the debate as to whether tongue-tie impairs breastfeeding.

A number of interesting functional studies have monitored tongue movement during breastfeeding and have demonstrated that the tongue is a major component of the suckling reflex⁷⁻¹⁰. In general terms, the initial function of the tongue is to help draw the breast into a correct position in the baby's mouth at the start of breastfeeding (initial latching). The

tongue then forms a groove along its length that provides a channel to maintain breast position, as well as holding the milk at the back of the tongue before swallowing is initiated. The tongue movement during suckling involves elevation of the tongue tip which traps milk in the front of the breast, before a wave of compression passing from the tip to about halfway along the tongue presses milk from the areola to the nipple. The pressure within the mouth is then reduced by the back of the tongue dropping to the floor of the mouth enabling milk to be expelled from the nipple by a combination of compression and suction. Efficient breastfeeding therefore, relies on the baby having an adequate length of free tongue tip, having adequate overall tongue movement, and also having sufficient flexibility of the floor of the mouth. Infants with tongue-tie attempt to compensate for restriction in these components in a number of ways¹¹. First, they use their jaws to increase the compression on the breast. This is often also accompanied by a shallow latch onto the breast. The increase in pressure leads

Appearance Items	Function Items
Appearance of tongue when lifted	Lateralisation
2: Round or square	2: Complete
1: Slight cleft in tip apparent	1: Body or tongue but no tongue tip
0: Heart or V-shaped	0: None
Elasticity of frenulum	Lift of tongue
2: Very elastic	2: Tip to mid-mouth
1: Moderately elastic	1: Only edges to mid-mouth
0: Little or no elasticity	0: Tip stays at lower alveolar ridge or rises to mid-mouth only with jaw closure
Length of lingual frenulum when tongue lifted	Extention of tongue
2: >1 cm	2: Tip over lower lip
1: 1 cm	1: Tip over lower gum only
0: <1 cm	0: Neither of the above, or anterior or mid-tongue humps
Attachment of lingual frenulum to tongue	Spread of anterior tongue
2: Posterior to tip	2: Complete
1: At tip	1: Moderate of partial
0: Notched tip	0: Little or none
Attachment of lingual frenulum to inferior alveolar ridge	Cupping
2: Attached to floor of mouth or well below ridge	2: Entire edge, firm cup
1: Attached just below ridge	1: Side edges only, moderate cup
0: Attached at ridge	0: Poor or no cup
	Peristalsis
	2: Complete, anterior or posterior
	1: Partial, originating posterior to tip
	0: None or reverse

TABLE 2. Hazelbaker Assessment Tool for lingual frenulum function.

to the mother sensing that the breast is being 'chewed' and in turn leads to nipple soreness and cracking. As the nipples become painful, the milk reflex slows and the baby has to further increase jaw pressure, establishing a vicious circle of increasingly painful suckling. Secondly, they use their lips instead of their tongues to move milk from the breast. This can be observed when the lips are turned outward rather than inward during breastfeeding. This can lead to frequent 'delatching' during feeding as well as feeds becoming prolonged, even if latching is maintained.

Clearly, many babies with tongue-tie compensate well, achieving effective breastfeeding which results in good weight gain and which is well tolerated by the mother. This is not surprising if we consider the spectrum of appearance and function of tongues with tongue-tie. However, the important question to consider, is does division in those who do not compensate well, enable breastfeeding to subsequently be established? There are a number of studies that help answer this.

The most significant of these is a randomised controlled trial in which babies with tongue-tie and feeding difficulties were randomised to either tongue-tie division (28 babies) or no division but intensive support of a lactation consultant (29 babies)². The mean age of the babies was 20 days (range 3 to 70) and follow-up was four months. In the division group, 95% of breastfed babies showed improvement in breastfeeding within 48 hours, compared with only 5% in the no division group. This controlled study added further support to a previous case-series by the same team in which 215 infants with tongue-tie and difficulties with breastfeeding who underwent tongue-tie division were studied¹². In that study, 80% achieved better breastfeeding within 24 hours, and 95% of infants could protrude their tongues at three months. Interestingly two patients had increased difficulty feeding after division. A similar case series of 123 babies with tongue-tie by Ballard et al³ demonstrated that 83% of babies with failure to thrive resumed breastfeeding within five days of the procedure and achieved a normal rate of growth. There was an 89% improvement in maternal comfort during breastfeeding in this series. A smaller case series from Oregon¹³ and a very small (12 patients) prospective cross-over trial of tongue-tie division and breastfeeding¹⁴, have also both

demonstrated a significant improvement in breastfeeding after division of tongue-tie in those babies with feeding difficulties.

Clearly larger controlled trials need to be performed in order to answer this question conclusively. However, there is enough data available to conclude that babies with tongue-tie and significant problems with breastfeeding, who have undergone assessment by a lactation consultant, should be referred to an appropriate specialist for consideration of tongue-tie division. Indeed, in December 2005, a guideline for division of tongue-tie for breastfeeding was issued by the National Institute for Health and Clinical Excellence (NICE) and this concluded:

"current evidence suggests that there are no major safety concerns about division of ankyloglossia (tongue-tie) and limited evidence suggests that this procedure can improve breastfeeding. This evidence is adequate to support the use of the procedure provided that normal arrangements are in place for consent, audit, and clinical governance"¹⁵.

Speech

One of the other principle reasons that parents request division of their child's tongue-tie is the widely held belief that tongue-tie can impair normal speech development. However, what is the evidence for this? In the study by Messner⁴, 60% of otolaryngologists, 50% of speech pathologists, but only 23% of paediatricians believed that tongue-tie is at least sometimes associated with speech difficulties. The real problem in answering this question is that to date there are no good controlled trials investigating tongue-tie and onset of speech difficulties prospectively.

Many published cases of tongue-tie and impaired speech are based on the observation that established speech difficulties can be associated with tongue-tie in some children, rather than definite evidence that it actually causes speech impairment. Certainly tongue-tie does not seem to be the cause of speech prevention or delay³. However, many clinicians believe that it can cause articulation difficulties in some patients. If the tongue tip is completely restricted, then perhaps understandably, the articulation of the sounds 't', 'd', 'l', 'th', and 's' may be affected¹⁶. A number of simple articulation tests have been suggested for assessing this¹⁷. A child who has tongue-tie and

difficulties with these sounds may well benefit from tongue-tie division. At least by optimising tongue movement, speech therapy can be maximally beneficial. It is important however, to first fully assess the child for other causes of speech difficulties.

Oral hygiene/dentition

Dentists frequently diagnose tongue-tie as part of their regular dental examinations and in some countries, lactation specialists principally refer children to dentists for tongue-tie division. However, one of the indications for tongue-tie that is often understated is impairment of oral hygiene and dentition. The tongue is frequently used by all of us for extracting pieces of food from between our teeth, and tongue movement also ensures movement of saliva around the mouth. Several groups have advocated division of tongue-tie if oral hygiene is affected^{17,18}, but no prospective, controlled studies are available.

Problems with dentition have been reported with tongue-tie including lower incisor deformity, gingival recession, and malocclusions¹⁹. However, the evidence is not strong enough to recommend prophylactic division of tongue-tie in order to prevent malocclusion. Often these conditions are associated with additional abnormalities such as deviation of the epiglottis or larynx²⁰. It is widely accepted that the tongue can influence face development and cases of impaired maxillary and mandibular development being resolved by tongue-tie division have been reported²¹.

Social tongue movement

The tongue is used for a wide variety of social activities including licking ice creams, playing musical instruments (particularly woodwind), and kissing. All these activities rely on good tongue protrusion and elevation and there are a number of reports indicating that these can be impeded by tongue-tie and in turn improved with tongue-tie division^{17, 22-24}. An interesting study, albeit small, of adolescent and adult patients aged between 14 and 68 years with previously untreated tongue-tie, indicated that 93% noted functional impairment and 57% mechanical limitations such as kissing and licking of lips, and that tongue function improved both subjectively and objectively in all patients undergoing division in this group²³. Whilst this and other studies are not randomised or controlled, they do

suggest that benefit can be achieved by dividing tongue-tie in a significant number of patients with these indications. It can also be reasonably postulated that prophylactic division of tongue-tie may prevent these difficulties developing later on, but this stance cannot be supported by clear data.

Timing and technique of division

The timing of tongue-tie division is largely related to the indication for division. Clearly if difficulty with breastfeeding is the reason for division, it is important that this is performed in the neonatal period to enable prompt re-establishment of breastfeeding and to prevent soreness and cracking of the mother's nipples. Therefore, when planning resources for this group of patients, it must be appreciated that whilst the condition itself is not life threatening, it cannot be treated electively. Indeed, any centre providing neonatal tongue-tie division, needs to be able to provide division within a couple of weeks of presentation.

When performed in a baby under three months of age, tongue-ties are usually divided without general anaesthesia, and can either be performed with blunt-ended scissors or bipolar diathermy. Topical anaesthesia is applied. The procedure is usually well tolerated with no more distress to the baby than having an injection. The key requirement is that the infant is held as still as possible during the division and that the procedure is abandoned if undue struggling is encountered (this is very rare in experienced hands) so as not to risk damage to the underlying salivary ducts. After division with scissors, a small amount of bleeding is encountered, but this is usually self-resolving. Diathermy division avoids this.

If feeding in the newborn with tongue-tie is normal and weight gain adequate, it is customary for most clinicians to wait until after the age of six months before division. One reason for this is that a number of tongue-ties will resolve 'spontaneously', often by getting stretched or caught on a tooth. However, if tongue-tie is still present after this and the child fulfils the criteria for division and the parents are keen for division, there is little point in delaying division beyond one year of age. It is imperative however, that the parents clearly appreciate the relative indications for division and can give truly informed consent.

In this older age group, division is usually performed under a short general anaesthetic. In addition to being much kinder for the child, this also allows clear visibility of the salivary ducts. A wide number of different procedures have been reported for division of tongue-tie in the older child including simple linear division by scissors or bipolar diathermy (frenotomy or frenulotomy), excision of the frenulum with simple closure of defect (frenectomy), and excision with z-plasty repair (frenuloplasty)²⁵. Indeed, elaborate variations of these themes have been recommended including the use of laser²⁶ and an elaborate four-flap z-frenuloplasty²⁷. The choice of procedure seems to be related to the surgical specialty of the person dividing, with plastic surgeons opting for the most complex procedures²⁵. However, there is no strong evidence that more complex procedures confer any advantage over more simple techniques²⁸. Complications of tongue-tie division include bleeding, infection, damage to the salivary ducts and damage to the tongue substance itself. All these complications should be rare if the procedure is undertaken carefully.

Conclusions

Tongue-tie affects a considerable number of infants and children. It is perhaps interesting that such a seemingly simple condition can cause such controversy and diversity of opinions! However, it is important that accurate information and guidance is given to parents with regard to the indications and potential benefits of tongue-tie division, and that appropriate provisions are in place for those infants that require division.

References

- Wallace A.F. Tongue Tie. *Lancet* 1963; **13**: 377-88.
- Hogan M., Westcott C., Griffiths M. Randomized, controlled trial of division of tongue-tie in infants with feeding problems. *J Paediatr Child Health* 2005; **41**(5-6): 246-50.
- Ballard J.L., Auer C.E., Khoury J.C. Ankyloglossia: Assessment, incidence, and effect of frenuloplasty on the breast-feeding dyad. *Paediatrics* 2002; **110**(5): e63.
- Messner A.H., Lalakea M.L. Ankyloglossia: Controversies in management. *Int J Paediatr Otorhinolaryngol* 2000; **54**(2-3): 123-31.
- Lalakea M.L., Messner A.H. Ankyloglossia: Does it matter? *Paediatr Clin North Am* 2003; **50**: 381-97.
- UNICEF. Towards a national breastfeeding policy. UNICEF UK Baby Friendly Initiative, 1997.
- Ardran G., Kemp F., Lind. A cineradiographic study of breastfeeding. *Br J Radiology* 1958; **31**(363): 156-62.

- Bosma J., Hepburn, L., Josell S.L., Baker K. Ultrasound demonstration of tongue motions during suckle feeding. *Dev Med Child Neurol* 1990; **32**: 223-29.
- Voloschin L.M., Althabe O., Olive H., Diana V., Repezza B. A new tool for measuring the suckling stimulus during breastfeeding in humans: The orokinetogram and the Fourier series. *J Reprod Fertil* 1998; **114**(2): 219-24.
- Tamura Y., Horikawa Y., Yoshida S. Co-ordination of tongue movements and peri-oral muscle activities during nutritive suckling. *Dev Med Child Neurol* 1996; **38**(6): 503-10.
- Genna C.W. Tongue-tie and breastfeeding. *Leaven* 2002; **38**(2): 27-29.
- Griffiths D.M. Do tongue-ties affect breastfeeding? *J Human Lactation* 2004; **20**: 409-14.
- Masiatis N.S., Kaempff J.W. Developing a frenotomy policy at one medical center: A case study approach. *J Human Lactation* 1996; **12**: 229-32.
- Dolberg S., Botzer E., Grunis E., et al. A randomised, prospective, blinded clinical trial with cross-over of frenotomy in ankyloglossia: Effect on breast-feeding difficulties. *Pediatric Research* 2002; **52**: 822.
- National Institute for Health and Clinical Excellence. Division of ankyloglossia (tongue-tie) for breastfeeding. December 2005; www.nice.org.uk/IPG149distributionlist.
- Kupietzky A., Botzer E. Ankyloglossia in the infant and young child: Clinical suggestions for diagnosis and management. *Pediatric Dentistry* 2005; **27**(1): 40-46.
- Ketty N., Sciuolo P.A. Ankyloglossia with psychological implications. *ASDC J Dent Child* 1974; **41**: 43-46.
- Young E.C., Sacks G.K. Examining for tongue tie. *Clin Paediatr* 1979; **18**: 298.
- Williams W.N., Waldron C.M. Assessment of lingual function when ankyloglossia (tongue-tie) is suspected. *J Am Dent Assoc* 1985; **110**: 353-26.
- Mukai S., Mukai C., Asaoka K. Congenital ankyloglossia with deviation of the epiglottis and larynx: Symptoms and respiratory function in adults. *Ann Otol Rhinol Laryngol* 1993; **102**(8): 620-24.
- Defabianis P. Ankyloglossia and its influence on maxillary and mandibular development. (A seven year follow-up case report). *Funct Orthod* 2000; **17**(4): 25-33.
- Horton C.E., Crawford H.H., Adamson J.E., Ashbell T.S. Tongue tie. *Arch Otolaryngol* 1971; **94**: 548-57.
- Lalakea M.L., Messner A.H. Ankyloglossia: The adolescent and adult perspective. *Otolaryngol Head Neck Surg* 2003; **128**(5): 746-52.
- Wright J.E. Tongue-tie. *J Paediatr Child Health* 1995; **31**(4): 276-78.
- Brinkmann S., Reilly S., Meara J.G. Management of tongue-tie in children: A survey of paediatric surgeons in Australia. *J Paediatr Child Health* 2004; **40**: 600-05.
- Kato J., Jayawardena J.A., Wijeyeweera R.L., Moriya K., Takagi Y. Application of a CO₂ laser for oral soft tissue surgery in children in Sri Lanka- introduction of a laser through activities of aid to a developing country. *Kokubyo Gakkai Zasshi* 2002; **69**(1): 34-38.
- Heller J., Gabbay J., O'Hara C., Heller M., Bradley J.P. Improved ankyloglossia correction with four-flap Z-frenuloplasty. *Ann Plast Surg* 2005; **54**(6): 623-28.
- McBride C. Tongue-tie. *J Paediatr Child Health* 2005; **41**: 242.